

## Introduction

Since early 2005 has Maya Posch, official name Thijs Posch, been trying to figure out how her body exactly works. Ever since her early youth there has been confusion from both her side and from her environment, including her own family and parents, about her body. Nobody has ever accepted her as being male, least of all herself.

The past 4.5 years she has had various tests performed, both in and outside the Netherlands, and has visited or contacted various clinics and hospitals. The result is a collection of contradicting conclusions, no facts and no treatments. She has started on her own with hormone therapy in 2007 to create a female hormone balance, as this would better fit her body.

Maya has a feminine skeleton build, including secondary feminine characteristics, no adam's apple, partially developed male genitals (no foreskin, partially descended testicles, no oil glands). Maya was part of a twin in the womb, with a merging of both embryos being a possibility. Important questions are what the explanation is for this mixture of male and female characteristics, and how her body is constructed exactly.

Also important for Maya is the possibility to have an official name and gender change executed, so that in her daily life she won't have to deal with a double identity anymore. Recognition of her condition would also mean full financial compensation for all treatments and medicines.

**Update:** In 2010 Maya had her first name officially changed to Maya from her old name.

## Primary Points

In showing the irregularities in this case there are a few important points:

1. Feminine skeleton structure. The presence of a feminine pelvis, feminine curvature of the spine. The absence of any masculine characteristics in the skeleton.
2. The presence of a prostate. With physical examination and on MRI scans.
3. The presence of testicles. With physical examination and on MRI scans.
4. The presence of a closed-off vagina.
5. Genotype. Chimera/mosaic case?
6. Second MRI scan. A scan made by accident?

## Issues

In short the present medical situation can be summarized as follows: in two German clinics the presence of a vagina has been recognized using MRI images and the conclusion of hermaphroditism made. In the Netherlands two hospitals (Erasmus MC, VUMC) have drawn the conclusion that there is nothing special to be seen on those MRI images. In the Netherlands there's a general refusal

to perform any more tests or discuss the situation with Germany and others.

## **Evidence**

In the following sections the important points will be analyzed.

### ***1. Feminine skeleton structure***

This point has been completely ignored in the Dutch hospitals. In Germany the report from the first clinic has confirmed that the pelvis of Maya a feminine structure has. An external check confirms this too. Clothes sizes are standard feminine, no male characteristics apparent with the skull, arms are slightly bend outwards in neutral position, upper legs turned slightly inwards, curvature spine typically feminine.

### ***2. Presence prostate***

During an ultrasound in 2005 in a Dutch hospital the presence of a prostate has been acknowledged. In 2007 Maya has begun hormone therapy, which would have reduced the size of the prostate due to the new hormone balance and would have become virtually transparant on scans (inactive). During the MRI scan in Germany in 2007 no prostate was therefore detected, nor during a second opinion at the second German clinic. In the Netherlands both the Erasmus MC and VUMC claimed to see a normal prostate. This isn't physically possible. A physical examination at the AMC in late 2008 proved that the prostate has indeed become miniscule. Therefore one couldn't possibly have seen a regular prostate (density of tissue, size) on the MRI images.

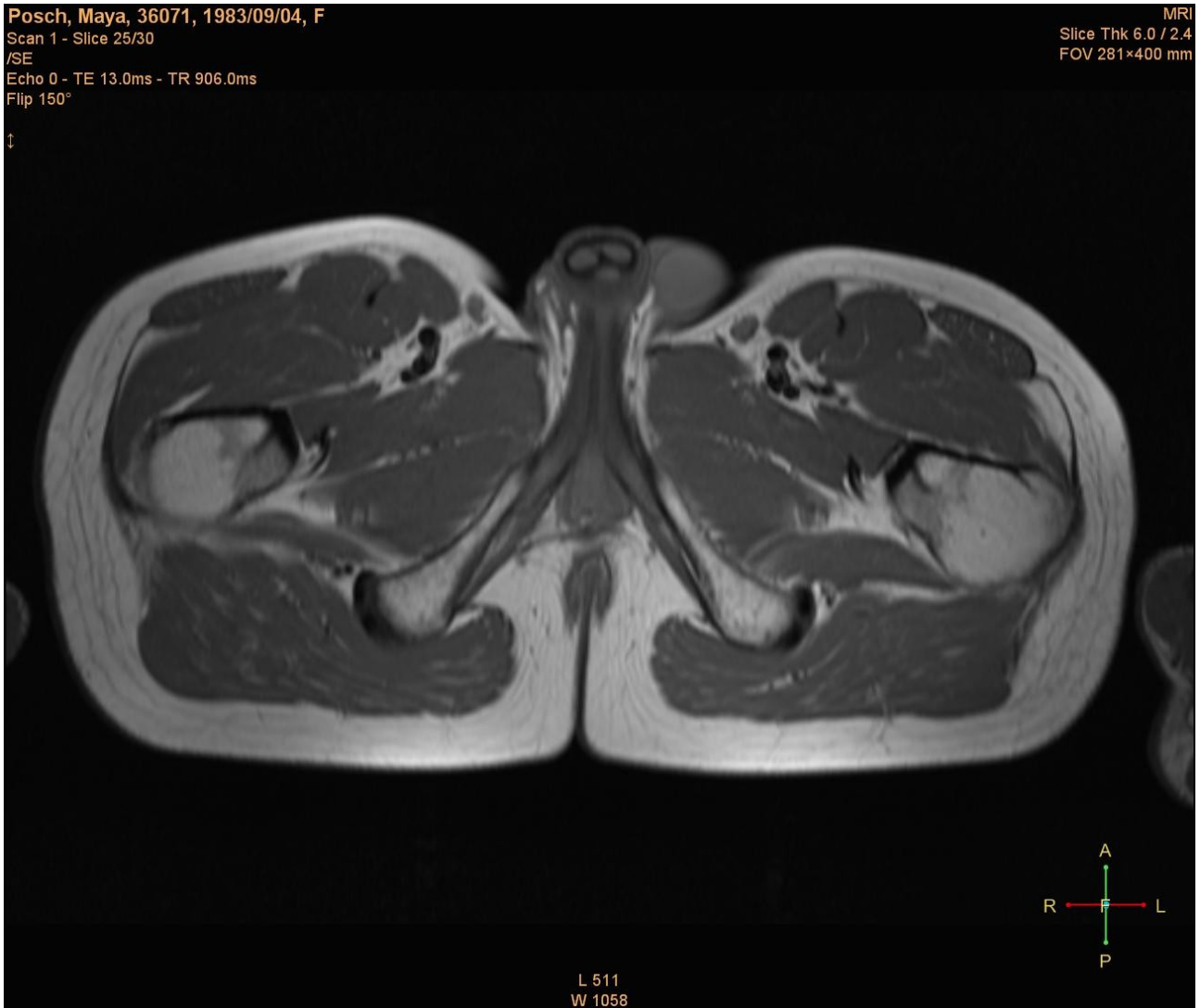**Update (2011/05/28):** Considering the clinical symptoms it's likely that Maya has a female prostate. This type of prostate would enlarge when exposed to increased levels of testosterone and produce more fluid than when exposed to feminine levels of testosterone (<0.7 nmol/L). Before starting hormone therapy Maya's testosterone level was about 2 nmol/L, which could have caused this effect. Considering that no ejaculatory fluids are being produced by the prostate in significant quantities after starting hormone therapy, this seems to be the correct theory.

### ***3. Presence testicles***

The reports from Germany do not mention the presence of testicles, only about the presence of the presence of the spermatic cords (visible on both sides).

The reports from the Netherlands (Erasmus MC, VUMC) report the presence of testicles at both sides. However, this isn't possible, since due the partial descending of the testicles these tend to retreat into the body, and this also happened during the MRI scan for one of both testicles. This testicle is therefore not visible on the MRI images, and therefore could most definitely not have been called 'normal'. No mention of this (unusual location or absence of testicle) was made in either report.

In the below MRI image it is clearly visible how one of both testicles (right side) appears to be missing.

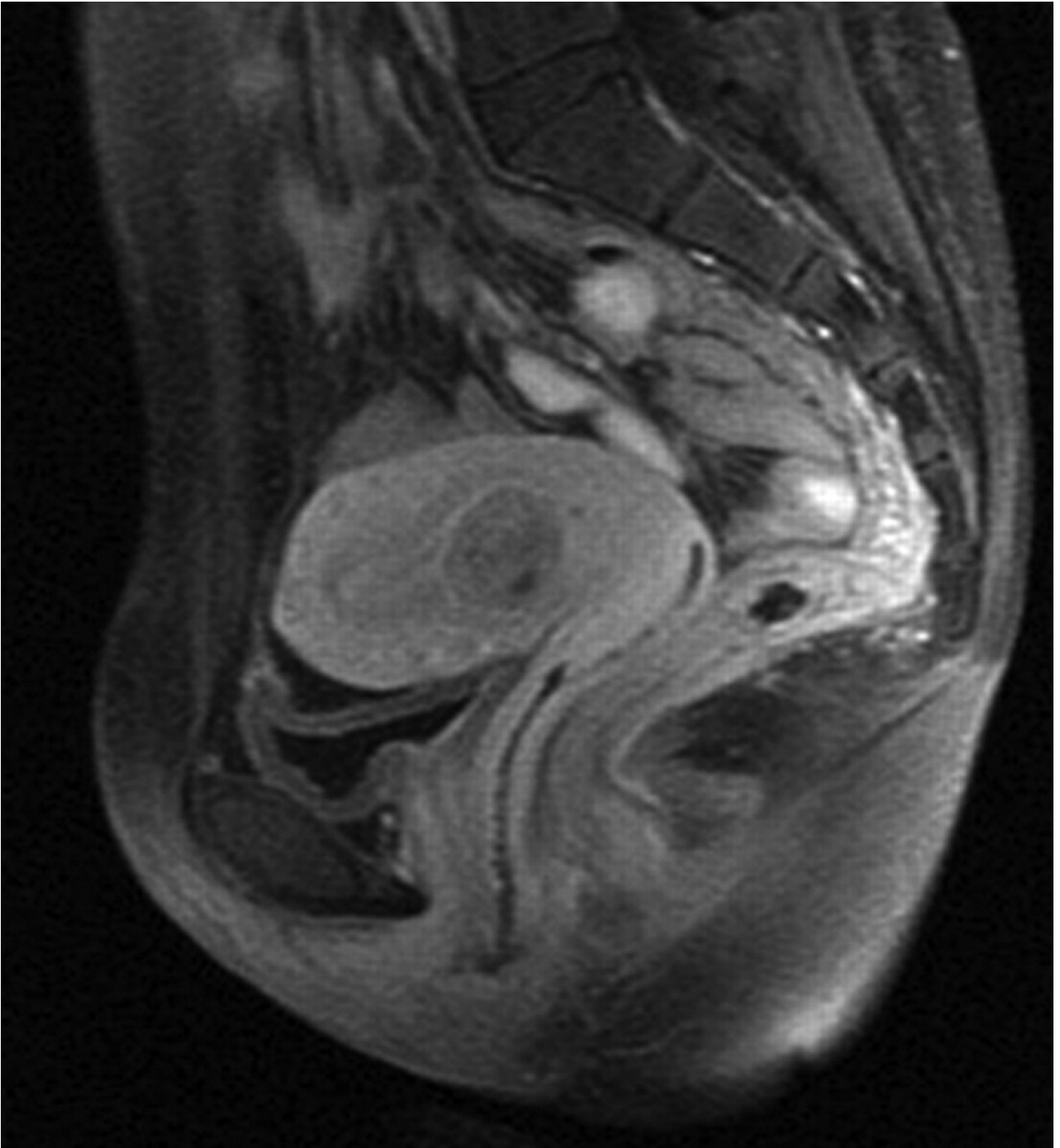

*Illustration 1: Missing testicle. Image from German MRI scan.*

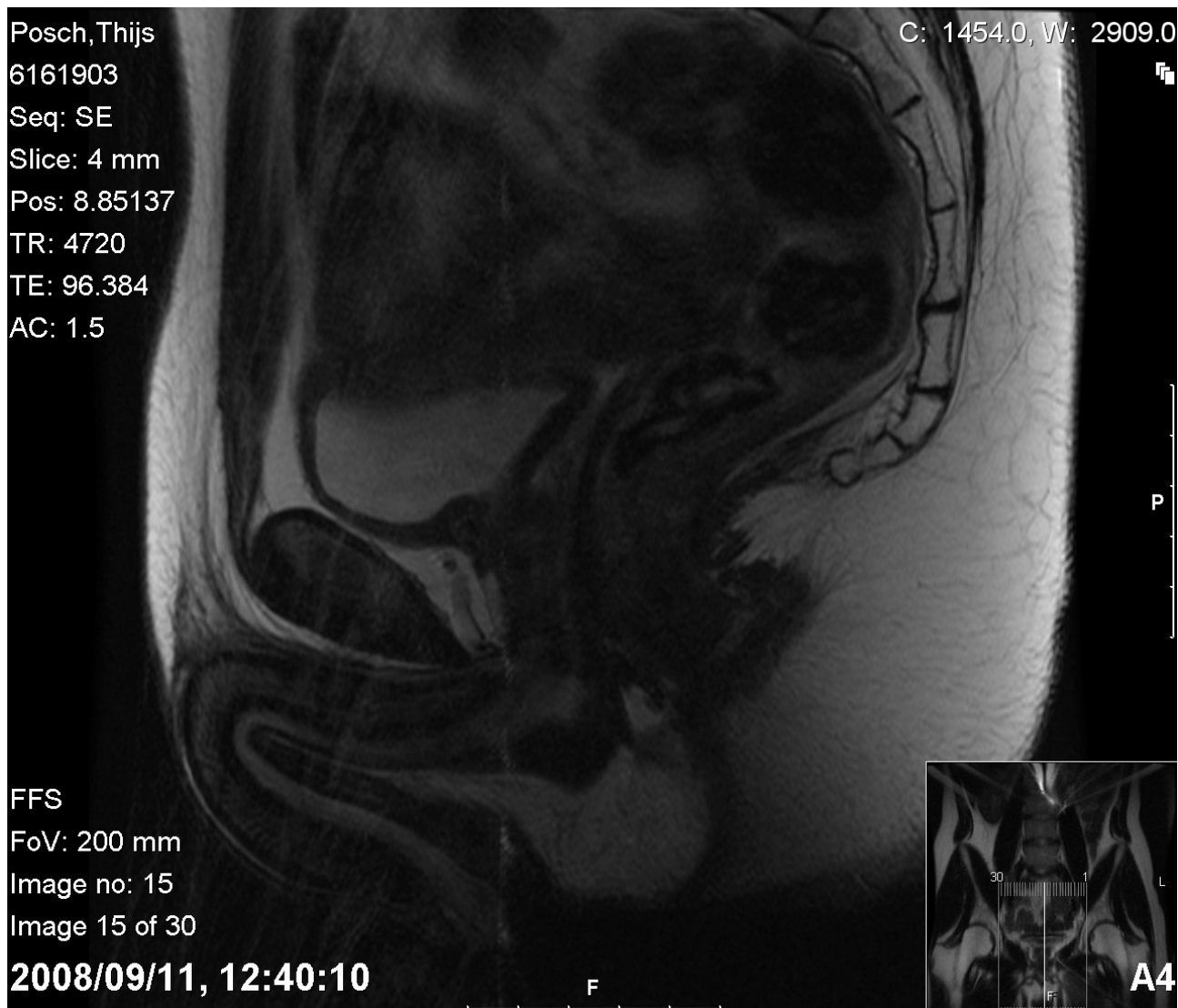#### **4. Presence closed-off vagina**

At first glance it appears to be an easy subject to investigate since a vagina is relatively easy to distinguish on an MRI scan. However, in this case both German clinics reported the presence of a vagina, while the Erasmus MC and VUMC insisted that there was nothing to be seen. During own study of those images together with comparison material the conclusion from the German clinics appears to be closer to the truth.

Observe the below images. The first is from an unknown woman, the second is from Maya. The first scan has a growth in the womb, but this is not of importance to this comparison.

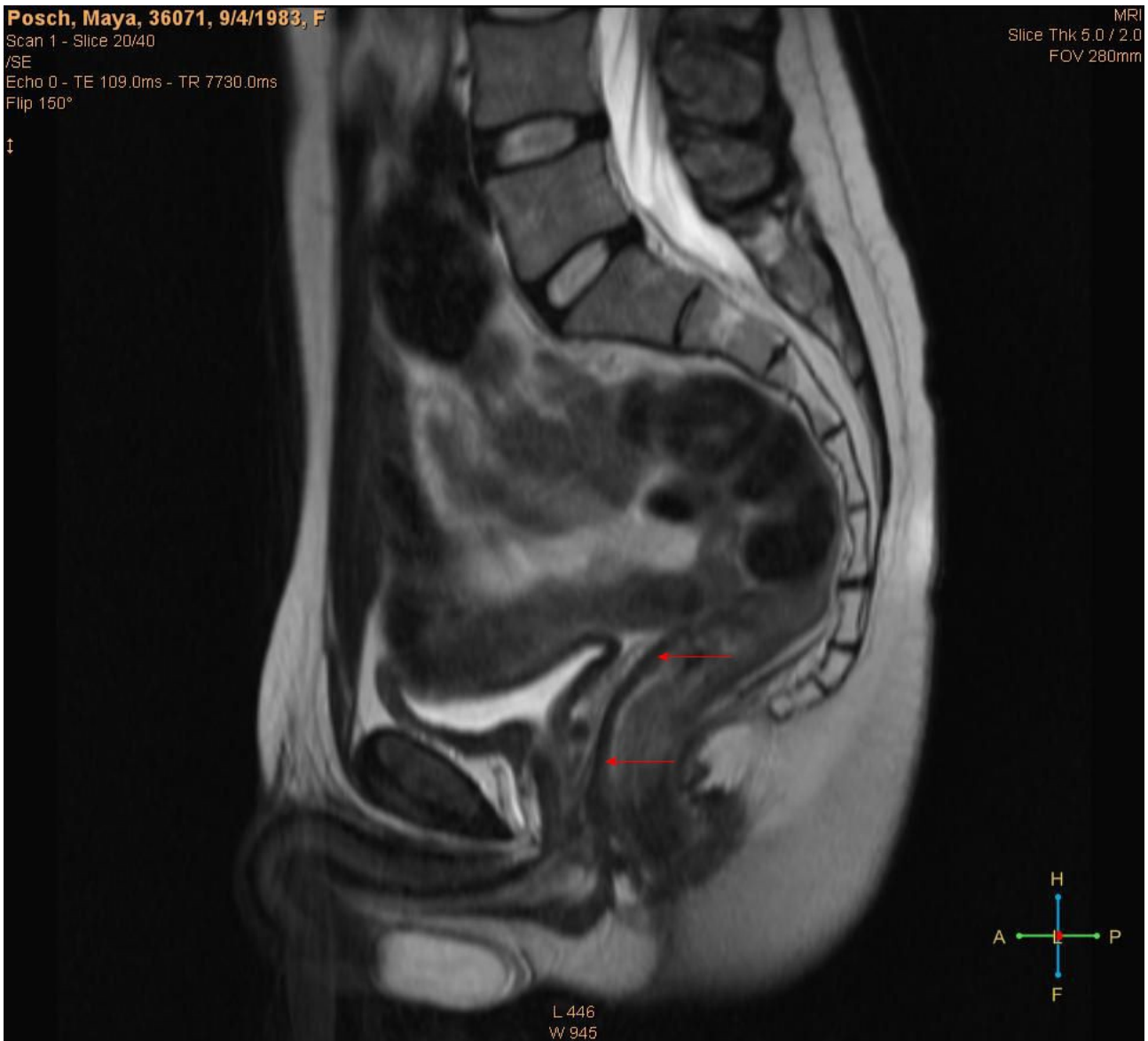


*Illustration 2: MRI image from unknown woman. Growth visible in womb, but no effect on other organs.*



*Illustration 3: MRI image made of Maya during scan at the Erasmus MC.*

To further clarify, another scan of Maya, but this time with the suspected vagina marked:



*Illustration 4: Location suspected vagina of Maya marked. From German scan.*

What's clear from this scan is that in all cases the vagina is clearly visible, and the orientation and position match. There are to our knowledge no other organs or structure for either men or women which would give a similar image.

## 5. Genotype

In 2007 a chromosome test has been performed on the blood of Maya. The result of this was 46, XY. Despite attempts to have a full chimera/mosaic test performed, any attempt at this has been blocked by the VUMC. At this moment Maya is searching for other ways to have this test performed.

**Updated (2011/05/28):** At the UMCG hospital the gender team has pretended to carry out a mosaic test in 2010. First on the white blood cells, which gave the same result as those from 2007, then at Maya's request a second tissue sample was tested, from the cheek slime cells. This also produced 46/XY. After this it was claimed that the exclusion of XX/XY multiple cell lines was 99%.

First of all, a single cell type with mosaicism is most likely from the same cell line, so the first test on the blood alone was very unlikely to show mosaicism and therefore quite useless. The second test didn't result in 99% exclusion, but only 75% (twice 50% in continuous probabilistic

distribution). A proper mosaic test would be performed on dozens of samples, from unique cell types.

## ***6. Second MRI scan***

On 2008/09/11 a second MRI scan was performed at the Erasmus MC. There was no indication prior to this that this scan would be requested. When asking an assistant prior to the scan about this, she showed the request form with the name and signature of the requesting doctor, Schipper. Maya had been in contact with this doctor prior. During a telephone conversation with doctor Schipper a few days later, he however insisted that he had no knowledge of this request, and also that there was nothing interesting to be seen on this latest scan. Up till today there is no explanation for why this scan would have been requested. It seems improbable that this scan would have been requested 'accidentally', especially considering the costs associated with performing such a scan.

## **Conclusions**

There are a lot of things in the case Maya Posch which are at the very least remarkable, possibly even illegal. There is evidence that in certain hospitals in the Netherlands there have been attempts to obscure and block research. The reason for this is unknown.

Further medical research is urgent to provide clarification, both about the MRI images (particularly the presence of a vagina), as well as about the full genotype. Maya is currently in a for her seemingly hopeless situation and has already attempted suicide twice. A repeat of this is not unlikely, which makes this situation even more urgent.